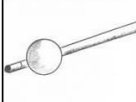
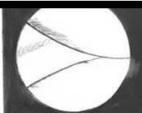
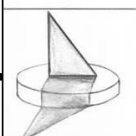





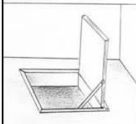



## Ostéochondrite disséquante du fémur distal

### Classification arthroscopique

Accadbled F, Vial J, Sales de Gauzy J. Osteochondritis dissecans of the knee. *Orthop Traumatol Surg Res.* 2018;104(1S):S97-S105. doi:10.1016/j.otsr.2017.02.016

Palpation		Inspection	
<div style="display: flex; justify-content: space-around; align-items: center;"> <div style="writing-mode: vertical-rl; transform: rotate(180deg);">Lésions stables</div> <div style="border-top: 1px dashed black; width: 50%;"></div> <div style="writing-mode: vertical-rl; transform: rotate(180deg);">Lésions instables</div> </div>	<b>Boule de billard</b> Aucune anomalie détectable		
	<b>Ombre</b> Cartilage intact mais discrètement surélevé		
	<b>Plis dans le tapis</b> Démarcation à type de ride ou replis		
	<b>Porte fermée</b> Fissuration		
	<b>Trappe</b> Clapet		
	<b>Cratère</b> Exposition osseuse	